

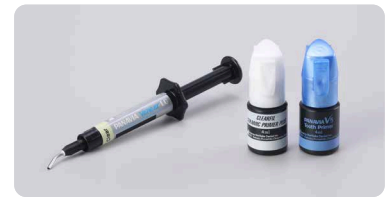Presentation of a study with illustrative cases

Yohei Sato, DMD, PhD
 Department of Removable Prosthodontics,
 Tsurumi University School of Dental Medicine, JAPAN

Keisuke Ihara, CDT
 I- Dental Lab, JAPAN

1 | Introduction

In recent years, the application and advancement of digital technology in dentistry has made it possible to accomplish the fabrication of highly accurate prosthetic zirconia appliances that were difficult to mill using the previously available technology. In addition, thanks to advances in adhesive dentistry and the advent of cements that bond strongly to a diverse range of materials, cements have come into wide clinical use that can cope with the many types of materials used for the fabrication of prosthetic appliances. At our hospital, we select the treatment method most suitable for each case by appropriately specifying various types of prosthetic appliance according to the status of each case. For example, we may specify zirconia prosthetic restorations fabricated by the CAD/CAM system, or silica-based ceramic prostheses, or those made of lithium disilicate glass, as the case dictates. "PANAVIA™ V5" is a resin cement system that bonds strongly to various types of prosthetic appliance, as well as to tooth structure. "PANAVIA™ Veneer LC", a new resin cement system developed by Kuraray Noritake Dental Inc., has suitable characteristics for bonding laminate veneers, using two types of primer that can be used in common with "PANAVIA™ V5". Here are some clinical examples of its advantages as a resin cement system used for laminate veneers restorations.



2 | Features

At our hospital, we often select laminate veneer restoration among the options for treating cases requiring esthetic improvement. There is now a gradual increase toward the use of laminate veneer restorations made with zirconia, making these a promising choice for consideration, in addition to lithium disilicate glass laminate veneers.

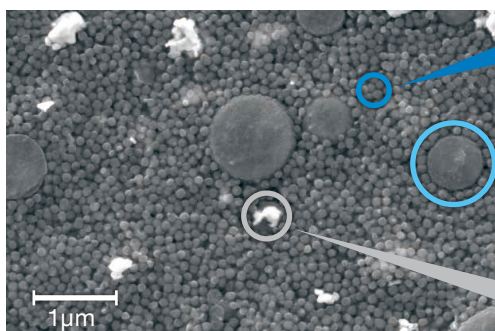
■ What makes a resin cement suitable for laminate veneer restoration ?

Generally, during laminate veneer restoration, a thin shell-like prosthetic appliance is bonded to the surface of the tooth. This means that, as compared with the resin cements used for prosthetic appliances for crowns, those used for laminate veneer restoration are required to have better flowability, or the characteristic of spreading smoothly, and a paste needs to be easy to shape so as not to displace the prosthesis as it is being fitted on the tooth. Moreover, laminate veneers are often used for the esthetic improvement of anterior teeth. Therefore, the resin cement used must provide sufficient working time (stability under ambient light), and excess cement must be easy to remove.

■ PANAVIA™ Veneer LC

This product is a light-cured resin cement system used for bonding laminate veneers, inlays and onlays that are sufficiently translucent for the purpose. "PANAVIA™ Veneer LC Paste", the main component of the "PANAVIA™ Veneer LC" system, is heavily loaded with microfillers, to make sure the resultant film is thin and the material is easy to handle. In addition, this resin cement system also includes "PANAVIA™ V5 Tooth Primer" (an abutment conditioning agent) and "CLEARFIL™ CERAMIC PRIMER PLUS" (a prosthesis conditioning agent) as standard components, providing a platform common to "PANAVIA™ V5".

High filler loading



Spherical silica filler

Flow and formability (not runny) combined
 Excellent polishability & gloss durability

Nano Cluster Filler

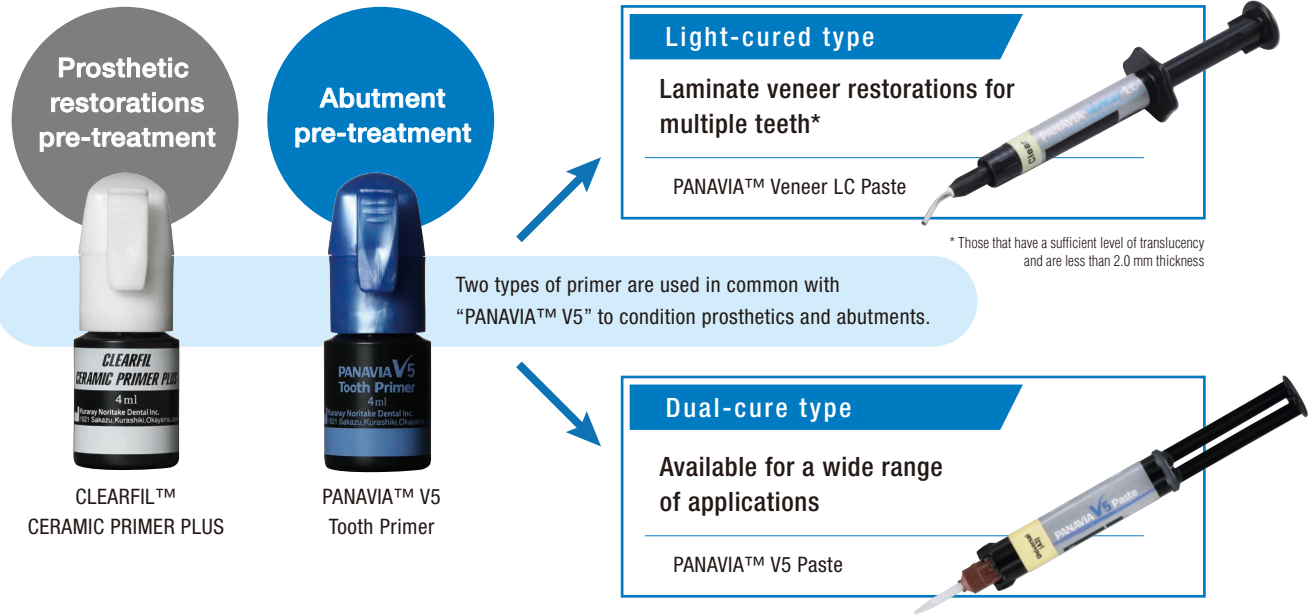
Reduction of stringing (Good handling)

Ytterbium trifluoride

Radiopacity

The use of these novel filler types results in an excellent level of polishability and gloss retention as well as easy handling.

Simple resin cement system




Specifications

Shade composition

- The same lineup of shades as that of "PANAVIA™ V5" (excluding Opaque)
- "PANAVIA™ V5 Try-in Paste" can also be used.

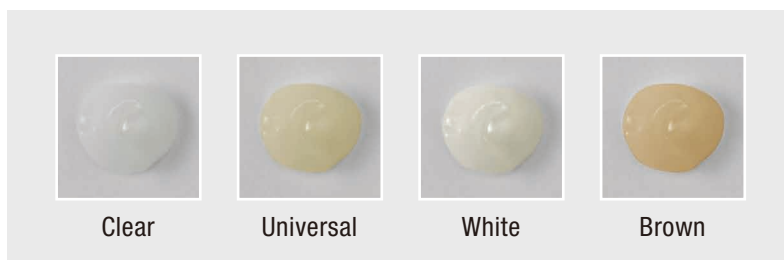PANAVIA™ Veneer LC Paste



Thickness: 1.0 mm



PANAVIA™ V5 Try-in Paste



There are not a few cases when a laminate veneer restoration is selected, in order to make a morphological correction while maintaining the color of the abutment intact. In such a case, it is preferable to select a resin cement that – to the extent possible – has little or no effect on the color of the prosthesis. "PANAVIA™ Veneer LC" comes in four shades (Clear, Universal, Brown and Bleach) that are adjusted for the same colors as those of "PANAVIA™ V5" (excluding Opaque). "PANAVIA™ V5 Try-in Paste", which makes it possible to simulate the color and film thickness of the final composite cement in the trial-fit stage, can be used with "PANAVIA™ Veneer LC" resin cement as a try-in paste for laminate veneer restoration. This also makes this product promising as a resin cement for laminate veneer restoration.

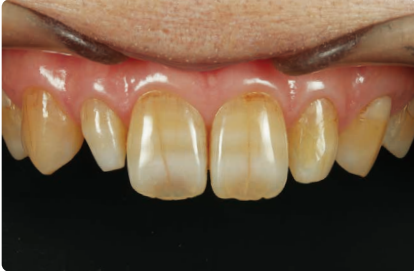3 | Case report

At our hospital, we use lithium disilicate glass and zirconia as materials when fabricating laminate veneer restorations. The following case reports are provided to illustrate using "PANAVIA™ Veneer LC" as a resin cement, with some technical points explained.

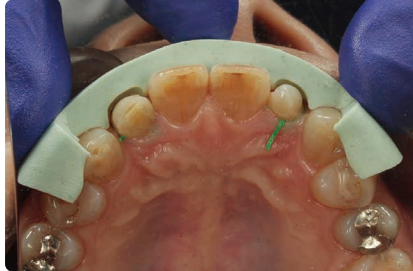Case 1

Laminate veneer restoration using lithium disilicate glass prosthetic restorations

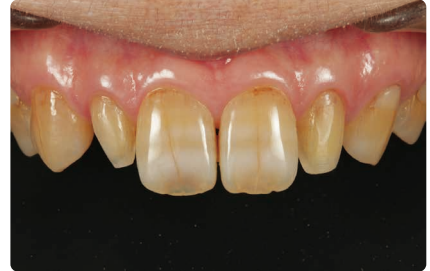("PANAVIA™ Veneer LC Paste" Clear was used.)



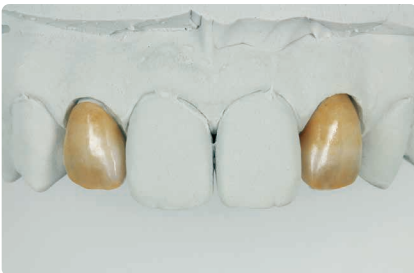1 The patient visited us with a chief complaint of a desire for improved esthetics of the maxillary right and left lateral incisors.



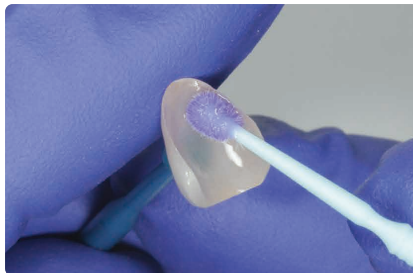2 A core fabricated from a diagnostic wax model was applied and the necessary clearances were determined.



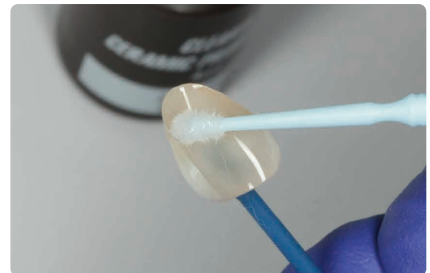
3 Since the teeth are microdonts, the preparation of each abutment was completed by simply exposing a fresh surface to be covered by the laminate veneers.



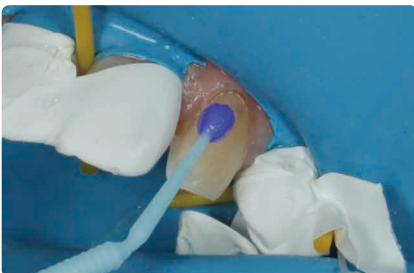
4 A layer of porcelain was applied on the lithium disilicate glass substrate, to make a complete laminate veneer.



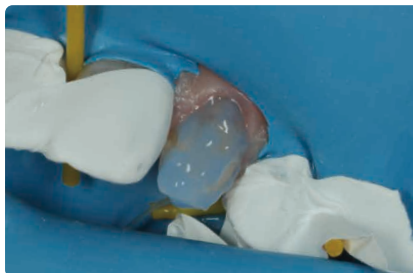
5 After a trial fitting, the inner surface of the laminate veneer was cleaned with "KATANA™ Cleaner". The inner surface was conditioned according to the prosthesis' IFU.



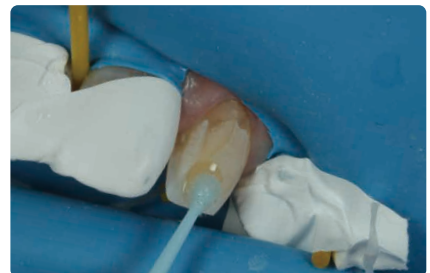6 "CLEARFIL™ CERAMIC PRIMER PLUS" was applied and dried to silane couple the restoration.



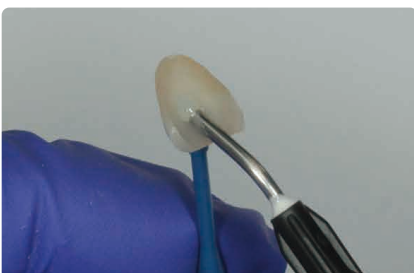7 After a trial fitting, "KATANA™ Cleaner" was applied to the abutment, and rubbed for more than 10 seconds. Then, it was washed off sufficiently (until the cleaner color had completely disappeared), and dried with compressed air.



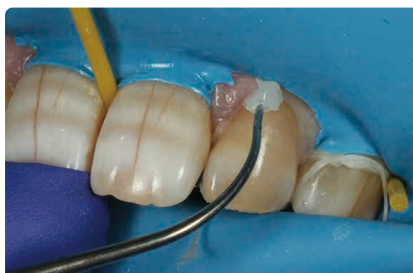8 K-ETCHANT Syringe was applied and left for 10 seconds before water-washing and compressed air-drying.



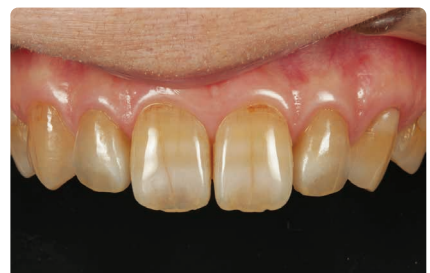9 "PANAVIA™ V5 Tooth Primer" was applied and left for 20 seconds before compressed-air drying.



10 "PANAVIA™ Veneer LC Paste" was applied to the inner surface of the laminate veneer.



11 The laminate veneer was seated and the fit checked. Then, the excess cement was tack-cured (not more than 1 second at any one point) and removed. Finally, the restoration was light-cured and finished.

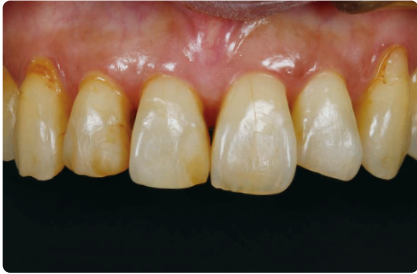

12 This photo shows the laminate veneer restorations one month after placement. The morphology and color of the right and left lateral incisors have been improved, providing a good balance to the entire anterior dentition.

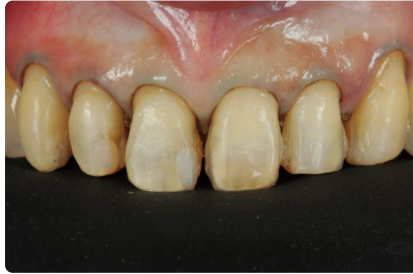Case 2

Laminate veneer restoration using "KATANA™ Zirconia" STML prostheses

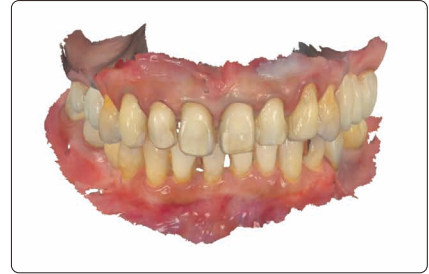("PANAVIA™ Veneer LC Paste" Clear was used.)



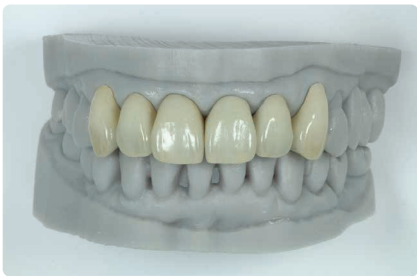1 The patient was referred to our hospital by an orthodontist. The chief complaints were improper esthetics of the teeth due to black triangles at the edges of the gaps between the teeth and occlusal wear of the teeth.



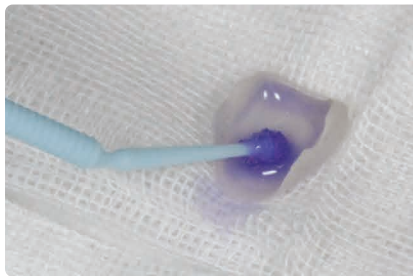
2 On the basis of the pre-treatment diagnosis using a mockup, the abutments were prepared without anesthesia, keeping in mind that the enamel should be preserved to the extent possible.



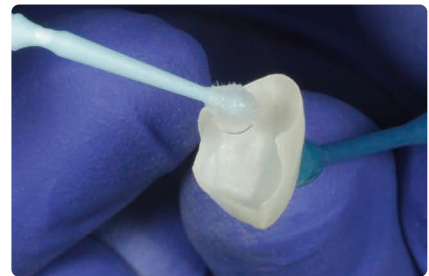3 Since a fixation retainer was installed on the palate side, it was difficult to take impressions using silicone. Therefore, an intraoral scanner for impression taking was used.



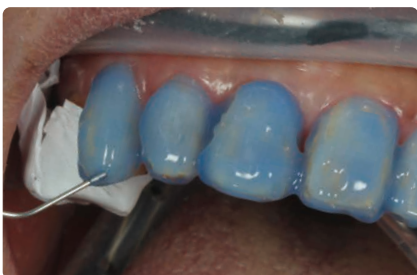4 A layer of porcelain on each of Noritake "KATANA™ Zirconia" STML substrates was applied to complete the laminate veneer restorations. The inner surface of each restoration was sandblasted, being careful to prevent chipping.



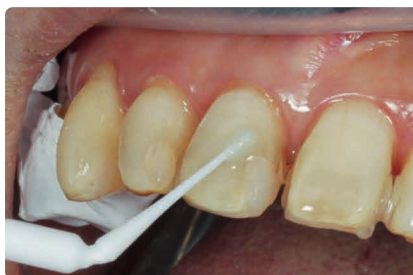5 After trial fitting, bonding inhibiting substances as blood and saliva were removed using "KATANA™ Cleaner".



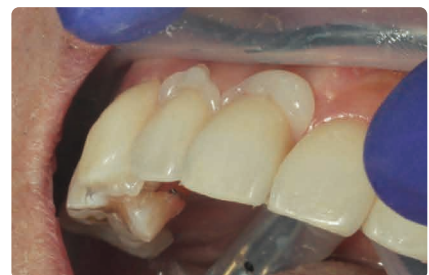6 "CLEARFIL™ CERAMIC PRIMER PLUS", which contains the phosphoric ester monomer MDP, was applied and dried using compressed air.



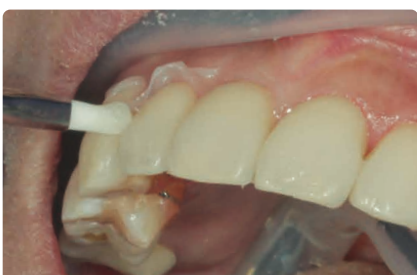7 The surface of each tooth was cleaned and treated with K-ETCHANT Syringe for 10 seconds before washing it away with water and compressed air-dried the area.



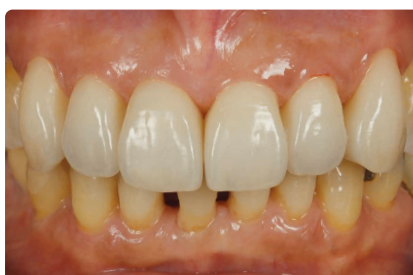8 "PANAVIA™ V5 Tooth Primer" was applied and left it for 20 seconds, then compressed air-dried it.



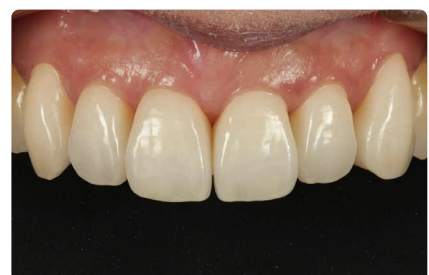9 "PANAVIA™ Veneer LC Paste" was applied and the laminate veneer was seated. For this case, we treated six teeth during one session.



10 The unpolymerized excess paste was removed with a brush. "PANAVIA™ Veneer LC Paste" is a light-cured type, which was designed to provide sufficient working time.



11 This photo shows the results after the final light curing. Since the excess cement was easily removed, there were almost no cement residues.

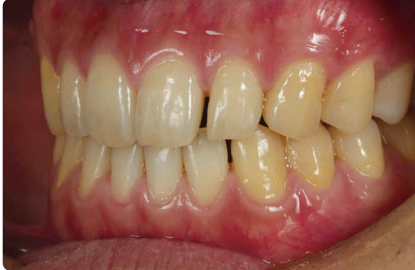

12 The photo shows the inside of the oral cavity one month after the fitting of the laminate veneer restorations. It can also be noted that the teeth's marginal gingiva has been improved, thanks to the good fit of the laminate veneer restorations.

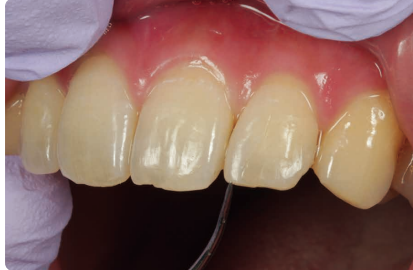Case 3

Laminate veneer restoration using silica-based ceramics

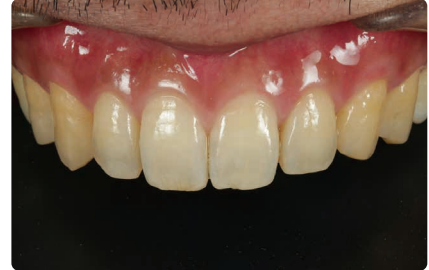("PANAVIA™ V5 Paste" Clear was used.)



1 The maxillary left lateral incisor is a microdont and there is a void on its mesial side.



2 In order to fill the mesial void, a veneer was suggested. Such veneer was cemented with "PANAVIA™ V5".

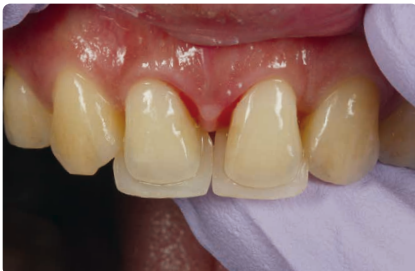

3 The photo shows the veneer 4 years after cementation. Due to appropriate post-operative maintenance, excellent esthetics have been maintained, with no discoloration at the cement line.

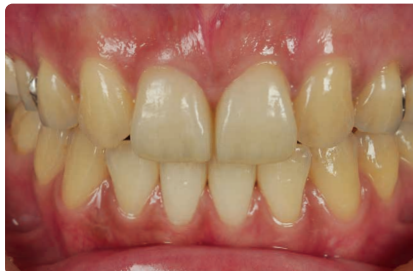Case 4

Laminate veneer restorations using lithium disilicate glass

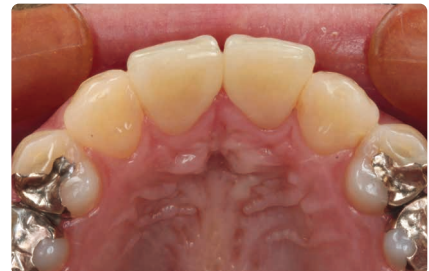("PANAVIA™ V5 Paste" Clear was used.)



1 The maxillary right and left lateral incisors had been brought into contact with the central incisors by an orthodontist. A set of sandwich veneers consisting of two veneers that covered the labial and palatal surfaces of each lateral incisor were fabricated.



2 The photo shows the sandwich veneers 2 years and 6 months after cementation. The esthetic appearance of the veneers is just as fine as when they were first cemented.



3 The occlusal surfaces of the restorations 2 years and 6 months after cementation. The cement line is also visually unobtrusive.

Laminate veneering is one of the most sensitive restoration techniques among bonding operations. As indicated in these case reports, it is absolutely necessary to perform the procedures in a reliable and accurate manner, including adequate tooth preparation and moisture control for strong bonding, securing the prosthetic appliances to the tooth structure, and removing excess cement. We have been using "PANAVIA™ V5" as a resin cement for almost all crown restoration cases, with good results. This indicates that we think it is a highly reliable cement (i.e., especially as shown by cases 3 and 4). It is particularly important, when fitting partial veneers that include additional veneers and laminate veneers for multiple teeth, to place the restoration in the correct position before a dual-cure cement begins to polymerize. Therefore, these treatments require a considerable level of concentration and speed. Using laminate veneers to treat multiple teeth may sometimes require dividing the number of teeth to be treated at one time into smaller groups (that is, using divided sessions) due to complicated cementation procedures involved. However, if the surface of a tooth adjacent to where a laminate veneer is planned to be fitted during the next session is contaminated with excess cement, this could have an adverse effect on the subsequent restoration placement. Therefore, we tend to try to fit all the restorations at one time, if possible. "PANAVIA™ Veneer LC", developed by Kuraray Noritake Dental, features the provision of sufficient working time, making it possible to seat laminate veneers over multiple teeth without stress. In addition, we can also use the same primers as are used for "PANAVIA™ V5", so there is no need to change the current cementation systems substantially and this is more economical. Because this is a light-cured system, it is necessary to take translucency into account, but it does cover almost all types of material and the thickness range of ordinary laminate veneers. The cement paste also has a fine consistency, almost completely eliminating the stress we used to experience during every previous laminate veneer treatment, such as having difficulty seating the restoration accurately and rushing to remove excess cement. It is expected that "PANAVIA™ Veneer LC" will become the resin cement of choice for laminate veneer restorations.

This product is a light-cured resin cement. Therefore, its Instructions for Use contains this precaution: "The product should be used only for restorations that are less than 2.0 mm thickness and of sufficient translucency." to permit light penetration for curing purposes. In addition, prior to using this product, it is also necessary to check its use conditions, including the usable prostheses, the prosthesis thickness that can be accommodated and the light-curing conditions, when using it for the restoration of metal oxide ceramics, such as zirconia. Generally, for zirconia laminate veneer restoration, the usable prosthesis thickness is set to less than 1.2 mm. Therefore, this product is appropriate for such a clinical use.

Restoration type and shade		Maximum restoration thickness	Type of curing light (Light intensity)		
			High-intensity BLUE LED ($\geq 1500 \text{ mW/cm}^2$)	BLUE LED (1000~1400 mW/cm^2)	Halogen lamp ($\geq 400 \text{ mW/cm}^2$)
Laminate veneer			Curing time		
Silica-based ceramic (e.g. conventional porcelain, lithium disilicate)	BL shades, A1, A2, A3, A3.5, B1, B2	2.0 mm	Three times for 3 sec. or Twice for 5 sec.	10 sec.	20 sec.
	Other shades			20 sec.	
Hybrid ceramic, composite resin	All shades	1.2 mm			
KATANA™ Zirconia STML/UTML/YML, KATANA™ Zirconia Block STML					
Inlays, onlays			Curing time		
Silica-based ceramic, hybrid ceramics, composite resin	All shades	2.0 mm	Three times for 3 sec. or Twice for 5 sec.	10 sec.	20 sec.
		1.2 mm			
KATANA™ Zirconia STML/UTML, KATANA™ Zirconia Block STML					
Shade and Depth of cure		Universal (A2), Clear, Brown (A4)			1.5 mm
		White			1.0 mm



EU Importer
Kuraray Europe GmbH
 Philipp-Reis-Strasse 4,
 65795 Hattersheim am Main, Germany
 Phone +49 (0) 69 305 35 835
 Fax +49 (0) 69 305 98 835
 www.kuraraynoritake.eu
 centralmarketing@kuraray.com

- Before using this product, be sure to read the Instructions for Use supplied with the product.
- The specifications and appearance of the product are subject to change without notice.
- Printed color can be slightly different from actual color.
- "PANAVIA" and "CLEARFIL" are trademarks or registered trademarks of KURARAY CO., LTD.
- "KATANA" is a trademark or registered trademark of NORITAKE CO., LIMITED.



Kuraray Noritake Dental Inc.
 1621 Sakazu, Kurashiki, Okayama 710-0801, Japan
 Website www.kuraraynoritake.com

R& Only



CE 0197